

Original research article

The importance of preoperative and perioperative Narrow Band Imaging endoscopy in the diagnosis of pre-tumor and tumor lesions of the larynx

Tomáš Filipovský^{1,2a}, David Kalfeřt^{3,4}, Eva Lukavcová¹, Šárka Zavázalová^{1,2}, Jiří Hložek^{1,2}, Daniel Kovář^{1,2}, Jaromír Astl^{1,2}, Richard Holý^{1,2a*}

¹ Military University Hospital Prague, Department of Otorhinolaryngology and Maxillofacial Surgery, Prague, Czech Republic

² Charles University, Third Faculty of Medicine, Prague, Czech Republic

³ Motol University Hospital, Department of Otorhinolaryngology and Head and Neck Surgery, Prague, Czech Republic

⁴ Charles University, First Faculty of Medicine, Prague, Czech Republic

Abstract

Introduction: Narrow band imaging (NBI) is an endoscopic imaging method intended for the diagnosis of mucosal lesions of the larynx that are not visible in white-light endoscopy, but are typical of pre-tumor and tumor lesions of the larynx.

The purpose of the study: To compare preoperative/perioperative white light endoscopy and NBI endoscopy with the results of histopathological examinations in pre-tumor and tumor lesions of the larynx.

Methods: A prospective study, over a period of five years (5/2018–5/2023), included 87 patients with laryngeal lesions aged 24–80 years. We evaluated preoperative/perioperative white light and NBI endoscopy, established a working prehistological diagnosis, and compared this with the definitive histopathological results of laryngeal biopsies.

Results: In relation to the definitive histology score, a statistically significant correlation was found between the evaluation of the finding and the definitive histology for preoperative and perioperative white light endoscopy and NBI endoscopy ($p < 0.001$). Both methods showed higher precision when used perioperatively.

Conclusion: NBI endoscopy is an optical method that allows us to improve the diagnosis of laryngeal lesions, perform a controlled perioperative biopsy, and refine the surgical scope. The NBI endoscopy is a suitable method for the diagnosis of early cancerous lesions of the larynx. The use of preoperative/perioperative NBI endoscopy allowed us to achieve a high level of agreement correlation ($p < 0.001$) between the prehistological working diagnosis and the final histopathological result. The NBI method proves its application in the diagnosis of pre-tumor and tumor lesions of the larynx.

Keywords: Endoscopy; Histopathological results; Laryngeal tumor; Narrow band imaging; Perioperative endoscopy; Preoperative endoscopy

Highlights:

- Prospective five-year study included 87 patients with laryngeal lesions.
- Compare pre/perioperative white light/NBI endoscopy to histopathological results.
- Statistically significant correlation ($p < 0.001$) for white light/NBI endoscopy.
- Both methods showed higher precision when used perioperatively.
- NBI endoscopy is a good optical method for improving the diagnosis of laryngeal lesions.

Introduction

Most laryngeal tumour lesions are diagnosed in the late stage of the disease, often with a poor prognosis. Surgical and oncological treatment of advanced tumors can then lead to mutilation of the patient and an even worse prognosis. Therefore,

early detection of tumor and pretumor lesions of the larynx is one of the most important factors for successful treatment (Holý et al., 2018).

Endoscopic methods help in early diagnosis. Standard white-light displays are recorded macroscopically distinct lesions. Narrow band imaging (NBI) is an endoscopic imaging method intended for the diagnosis of mucosal lesions of the

* **Corresponding author:** Richard Holý, Military University Hospital Prague and Third Faculty of Medicine, Department of Otorhinolaryngology and Maxillofacial Surgery, U Vojenské nemocnice 1200, 169 02 Praha 6, Czech Republic; e-mail: richard.holy@uvn.cz; <http://doi.org/10.32725/jab.2023.015>

^a These authors contributed equally to this research.

Submitted: 2023-08-16 • Accepted: 2023-09-13 • Prepublished online: 2023-09-22

J Appl Biomed 21/3: 107–112 • EISSN 1214-0287 • ISSN 1214-021X

© 2023 The Authors. Published by University of South Bohemia in České Budějovice, Faculty of Health and Social Sciences.

This is an open access article under the CC BY-NC-ND license.

larynx that are not visible in white-light endoscopy, but are typical of pre-tumor and tumor lesions of the larynx (Holý et al., 2018; Ni et al., 2011).

The principle of NBI endoscopy shows changes in mucosal vascularization using tissue illumination by a “narrow” band of the light spectrum. The method is based on the principle of different penetration depths of filtered light with a wavelength of around 400–430 nm and 525–555 nm. In the NBI mode, mucosal vascularization is shown with greater contrast than in white light mode. NBI Signs of tumor neoangiogenesis are irregularities of intraepithelial capillary loops (IPCL) and

“brown dots” spaced in a confined deposit of altered epithelium (Ni et al., 2011, 2019).

Observing changes in IPCL can help distinguish benign from malignant lesions (Lukes et al., 2014; Ni et al., 2019). We can classify NBI endoscopies as one of the so-called prehistological methods. In common practice, the NBI classification scale for vascularization evaluation according to Ni et al. in the range I. – Vc is used. Types I, II, III, IV are considered benign lesions of the larynx. Types Va, Vb, and Vc are considered malignant lesions (Campo et al., 2022; Ni et al., 2011, 2019) – see Fig. 1.

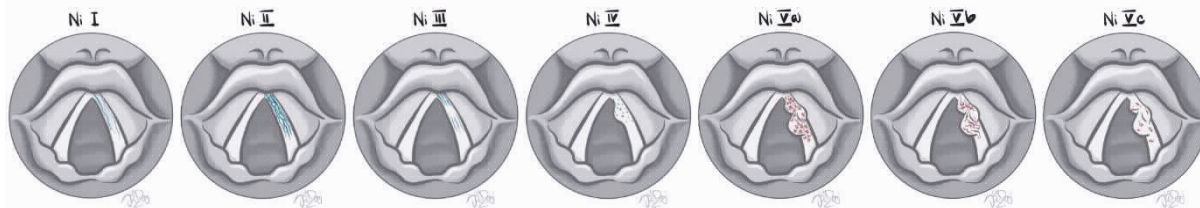


Fig. 1. Narrow Band Imaging (NBI) classification scale for vascularization evaluation according to Ni et al. in the range I. – Vc

Type I: thin, oblique vessels are interconnected, intraepithelial papillary capillary loops (IPCL) are almost invisible (Ni et al., 2011).

Type II: diameter of oblique vessels is enlarged, IPCL are almost invisible (Ni et al., 2011).

Type III: IPCL are obscured by white mucosa.

Type IV: IPCL can be recognised as small dots (Ni et al., 2011).

Type Va: IPCL appear as solid or hollow, with a brownish, speckled pattern and various shapes.

Type Vb: IPCL appear as irregular, tortuous, line-like shapes.

Type Vc: IPCL appear as brown dots, or tortuous, line-like shapes with irregular distribution, scattered on the tumour surface (Ni et al., 2011).

Currently, we can use NBI endoscopy not only preoperatively but also perioperatively. This makes it possible to assess not only the laryngeal lesion itself, but also influence the extent of surgery and further refine the resection margin, or perform a navigated biopsy (Piazza et al., 2010).

We use two basic types of endolaryngeal surgery: cold steel surgery and laser surgery. In both we use perioperative NBI mode for navigated biopsies (Slouka et al., 2015).

The purpose of this study is to analyze the results of preoperative NBI endoscopy versus perioperative NBI endoscopy versus histopathological results.

Materials and methods

Our prospective study was approved by the local Ethics Committee – Reference Number 108/17-29/2022. All patients signed an informed consent form.

Over five years, 5/2017–5/2023, 87 patients with laryngeal lesions were included. The group consisted of 31 females and 56 males. The mean age in the group was 58 years (range 24–80 years). We compared flexible preoperative/rigid perioperative white light endoscopy and NBI endoscopy, and prehistological working diagnosis, to the results of laryngeal histopathological examinations.

We used the NBI classification by Ni et al. Ni I, II, III – benign lesions, Ni IV – typical view for papilloma, and Ni V – malignant lesions.

All operations were performed by senior surgeons (co-authors) at Military University Hospital.

Inclusion criteria:

- Age over 18 years.
- Pathological preoperative laryngeal lesions.
- Performing flexible preoperative and rigid perioperative white-light endoscopy and narrow band imaging (NBI) endoscopy.

Exclusion criteria:

- Age below 18 years.
- Non-pathological preoperative laryngeal findings.
- Lack of preoperative and perioperative Narrow Band Imaging (NBI) endoscopy.

Investigation algorithm

1. Flexible preoperative NBI endoscopy (Olympus Exera II) and white light endoscopy NBI classification: scale for vascularization evaluation according to Ni et al. (2011). For the NBI examination, a grade IV finding was considered suspicious for papilloma. For the NBI examination, a grade V finding was considered suspicious for malignancy. White light: for statistical evaluation, the clinical findings of “suspicious” and “very suspicious” were used as suspicious of malignancy (see Table 1).

2. Perioperative rigid NBI endoscopy (Olympus Visera 4K UHD) and white light endoscopy. NBI classification: scale for vascularization evaluation according to Ni et al. (2011). For the NBI examination, a grade IV finding was considered suspicious for papilloma. For the NBI examination, a grade V finding was considered suspicious for malignancy. White light: for statistical evaluation, the clinical findings of “suspicious” and “very suspicious” were used as suspicious of malignancy (see Table 1).

3. Collection of histopathological samples.

4. Determination of working diagnoses: benign or premalignant or malignant mucosal pathologies.

5. Comparison of histopathological results with the working diagnoses.

Statistical analysis

Statistical analysis was performed using IBM SPSS Statistics (version 22.0; SPSS, IBM, Armonk, NY, USA) and MedCalc Software Ltd. Diagnostic test evaluation calculator was used – https://www.medcalc.org/calc/diagnostic_test.php (Version 20.211; accessed January 9, 2023). Data were analyzed using Fisher's exact test; p-values equal to or less than 0.05 were considered significant. Sensitivity and specificity, positive predictive value (PPV) and negative predictive value (NPV), and positive likelihood ratio (LR+) and negative likelihood ratio (LR-) were calculated with 95% of their corresponding 95% confidence intervals (CI). Sensitivity is the probability that a test result will be positive (suspicious for malignancy) if the Squamous cell carcinoma (SCC) is present (true positive rate). Specificity is the probability that a test result will be negative (non-suspicious for malignancy) if the Squamous cell carcinoma is not present (true negative rate). LR+ is the ratio between the probability of a positive test result (suspicious for malignancy) given the presence of the Squamous cell carcinoma and the probability of a positive test result (suspicious for malignancy) given the absence of the Squamous cell carcinoma. LR- is the ratio between the probability of a negative test result (nonsuspicious for malignancy see Table 1 and Table 3)

given the presence of the SCC and the probability of a negative test result (nonsuspicious for malignancy see Table 1 and Table 3) given the absence of the SCC. PPV is the probability that the Squamous cell carcinoma is present when the test is positive (suspicious for malignancy). NPV is the probability that the SCC is not present when the test is negative (nonsuspicious for malignancy).

Results

Preoperatively, 42 (48.3%) cases were considered nonsuspicious, 24 (27.6%) cases were suspicious, and 21 (24.1%) cases were very suspicious by white light.

Perioperatively, 47 (54.0%) cases were assessed as nonsuspicious, 23 (26.4%) cases were suspicious, and 17 (19.5%) cases were very suspicious by white light.

In relation to the definitive histology, a statistically significant relationship was found between the assessment of the findings and the definitive histology ($p < 0.001$ and $p < 0.001$, respectively) for both the preoperative and perioperative white light examination (Table 1).

Table 1. Correlation of preoperative and perioperative white light assessment findings in relation to definitive histology

White light evaluation		Definitive histology				p-value
		Benign		SCC		
		N	%	N	%	
Preoperative	nonsuspicious	42	100.0	0	0.0	<0.001*
	suspicious	23	95.8	1	4.2	
	very suspicious	9	42.8	12	57.1	
Perioperative	nonsuspicious	47	100.0	0	0.0	<0.001*
	suspicious	21	91.3	2	8.7	
	very suspicious	6	35.3	11	64.7	

Note: * Nonsuspicious for malignancy vs Suspicious for malignancy and Very suspicious for malignancy – depending on definitive histology (Fisher's Exact Test).

Preoperatively, 15 (17.2%) cases were graded I, 34 (39.1%) cases were graded II, 10 (11.5%) cases were graded III, 12 (13.8%) cases were graded IV, and 16 (18.4%) cases were graded V using NBI.

Perioperatively, NBI was used to evaluate grade I 17 (19.5%) cases, grade II 35 (40.2%) cases, grade III 11 (12.6%) cases, grade IV 11 (12.6%) cases, and grade V 13 (14.9%) cases.

A statistically significant correlation was found between the grade of the findings and the definitive histology ($p < 0.001$ and $p < 0.001$, respectively) in relation to preoperative and perioperative NBI (Table 2).

The sensitivity and specificity for the preoperatively performed white light examination were 100.00% and 56.76%, respectively. For the preoperatively performed NBI examination they were 69.23% and 90.54%, respectively (Table 3).

Table 2. Preoperative and perioperative NBI score in correlation with definitive histology

Ni classification	Preoperative NBI				Perioperative NBI			
	Definitive histology				Definitive histology			
	Benign		SCC		Benign		SCC	
	N	%	N	%	N	%	N	%
I	15	100.0	0	0.0	17	100.0	0	0.0
II	32	94.1	2	5.9	34	97.1	1	2.9
III	9	90.0	1	10.0	9	81.8	2	18.2
IV	11	91.7	1	8.3	11	100.0	0	0.0
V	7	43.8	9	56.3	3	23.1	10	76.9
p-value	<0.001*				<0.001*			

Note: * I–IV vs V depending on definitive histology (Fisher's Exact Test).

The sensitivity and specificity for the perioperative white light examination were 100.00% and 63.51%, respectively. For the perioperatively performed NBI examination they were 76.92% and 95.95%, respectively (Table 3).

Thus, both methods showed higher precision when used perioperatively (Table 3).

Table 3. The diagnostic success rate of NBI and white light for malignancy detection in relation to the time of performance

	Preoperative NBI		Preoperative white light	
	Value	95% CI	Value	95% CI
Sensitivity	69.23%	38.57% to 90.91%	100.00%	75.29% to 100.00%
Specificity	90.54%	81.48% to 96.11%	56.76%	44.72% to 68.23%
Positive Likelihood Ratio	7.32	3.31 to 16.17	2.31	1.78 to 3.00
Negative Likelihood Ratio	0.34	0.15 to 0.77	0.00	
Disease prevalence (*)	14.94%	8.20% to 24.20%	14.94%	8.20% to 24.20%
Positive Predictive Value (*)	56.25%	36.79% to 73.96%	28.89%	23.83% to 34.53%
	Perioperative NBI		Perioperative white light	
	Value	95% CI	Value	95% CI
Negative Predictive Value (*)	94.37%	88.08% to 97.43%	100.00%	
Accuracy (*)	87.36%	78.50% to 93.52%	63.22%	52.20% to 73.31%
Sensitivity	76.92%	46.19% to 94.96%	100.00%	75.29% to 100.00%
Specificity	95.95%	88.61% to 99.16%	63.51%	51.51% to 74.40%
Positive Likelihood Ratio	18.97	6.02 to 59.79	2.74	2.03 to 3.70
Negative Likelihood Ratio	0.24	0.09 to 0.65	0.00	
Disease prevalence (*)	14.94%	8.20% to 24.20%	14.94%	8.20% to 24.20%
Positive Predictive Value (*)	76.92%	51.41% to 91.31%	32.50%	26.28% to 39.41%
Negative Predictive Value (*)	95.95%	89.76% to 98.46%	100.00%	
Accuracy (*)	93.10%	85.59% to 97.43%	68.97%	58.14% to 78.45%

Note: * These values are dependent on disease prevalence [confidence intervals (CI)].

Discussion

Preoperative and perioperative Narrow Band Imaging endoscopy is an optical method (with a high degree of precision) for the diagnosis of laryngeal neoplasia and pre-tumor lesions of the larynx. The advantage of NBI endoscopy is that the result is available immediately, before histopathological results (Holý et al., 2018; Lukes et al., 2014; Piazza et al., 2011; Slouka et al., 2015). Ni et al. (2011, 2019) and Lu et al. (2021) indicate that there is a relatively good correlation between the endoscopic diagnosis of NBI and the pathological diagnosis.

The European Laryngological Society classification for vascular changes of NBI of glottic lesions is a highly reliable tool. Its systematic use allows for a better diagnostic evaluation of suspicious laryngeal lesions, reliably distinguishing benign ones from those with a diagnosis of papillomatosis, squamous intraepithelial neoplasia, or squamous cell carcinoma; thus paving the way towards confirmation of the optical biopsy concept (Missale et al., 2021).

Our results show the importance of endoscopy using both white-light and NBI modes. Preoperatively and perioperatively, we confirmed the significance of both light modalities in the diagnosis of laryngeal lesions at the significance level of p -value < 0.001. We agree with the opinion of the authors Ni et al. (2019) and Staníková et al. (2015) who reported that NBI endoscopy provides excellent results in the case of a clean surface of the observed mucosa. However, even NBI endoscopy

has its limits. The method is not suitable for the presence of necrotic tissue on the mucosal surface, whitish areas on the lesion surface, the stagnation of secretion on the mucosa, or post-radiation changes on the mucosa.

In these cases, the mucosal vascular plexus cannot be properly evaluated, which can lead to false negative results (Ni et al., 2011, 2019). Similarly, the authors Šatanková et al. (2021) reported that NBI endoscopy using the Ni classification has great potential to improve the diagnosis of precancerous and malignant lesions and is strongly correlated with histopathologic results. It serves as a useful adjunct to white-light endoscopy in the diagnosis of laryngeal and hypopharyngeal lesions.

Staníková et al. (2015) state that the early stages of squamous cell carcinoma of the larynx can be diagnosed using methods that are sometimes called pre-histological diagnosis.

These include NBI endoscopy, Lugol solution mucosal staining chromoendoscopy, autofluorescence endoscopy, contact endoscopy, or optical coherence tomography (Lukeš et al., 2014).

In our department, we use commonly NBI endoscopy and autofluorescence endoscopy. Additionally, we use the ORBEYE™ 4K 3D OLYMPUS perioperative video exoscope (see Fig. 2). The ORBEYE™ exoscope allows unique resolution and very detailed imaging of laryngeal tissues in high resolution and in 3D model. The use of the NBI mode, together with 3D imaging, allows for a far more precise guided biopsy or resection.

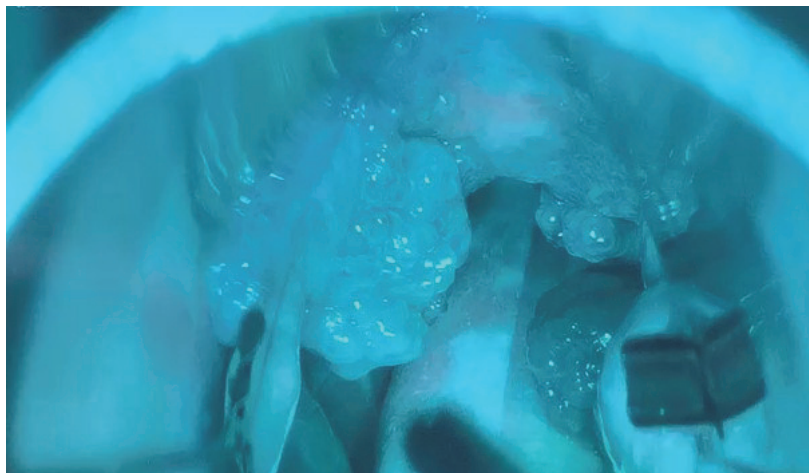


Fig. 2. Video exoscope ORBEYE™ 4K 3D OLYMPUS – perioperative NBI mode – papillomatosis of larynx (from first author's archive)

This method allows the entire surgical team to participate in surgery; they can all view the same images at the same time with a 3D resolution of the surgical field (Holý et al., 2018; Muscas et al., 2021).

Perioperative NBI endoscopy is of great significance when taking targeted biopsies during surgery, evaluating the mucosal spread of tumors, or determining safe resection lines. Using perioperative NBI endoscopy, a targeted biopsy, and more precisely, the extent of tumor mucosal changes, can be performed. We can then apply this knowledge to the planning of surgical or oncological therapies (Piazza et al., 2010, 2011).

NBI endoscopy and larynx papillomatosis

Lukes et al. (2014) reported, that in the case of 7 patients (8.5%), it was not possible to determine whether the findings supported a diagnosis of SCC or papillomatosis using IPCL and papillary arrangement.

In papillomas, IPCL changes were similar to those visible in cancers. Features significant for the improvement of endoscopic diagnosis were the observations of the surface of the lesions (in papillomas, a smooth surface was found in all cases, whereas carcinomas can show hyperkeratosis or a rough surface), laterality, and multiplicity of lesions. Furthermore, lesions affecting both vocal cords and multiple lesions were most frequently observed in papillomatosis (Adachi et al., 2015; Dippold et al., 2015; Lukes et al., 2014; Saraniti et al., 2022). We agree with data published by American authors, who found that an increase in vessel density and size can be observed in both late papillomas and carcinomas (Bolontrade et al., 1998). In our group of 87 patients, we had 11 patients with papillomas already detectable prehistologically (Ni IV) by preoperative/operative NBI endoscopy (91.7% and 100%, respectively). The data concurs with the data of the Czech authors Lukes et al. (2014). Dippold et al. (2015) stated that the detection of laryngeal papillomas and the correct number of identified papilloma lesions were more accurate with NBI endoscopy than with normal white light endoscopy. There was a significantly higher probability of detecting laryngeal papillomas using NBI endoscopy.

Adachi et al. (2015) and Mlčochová et al. (2020) reported that it is difficult to perioperatively localize all superficial papillomatous lesions when the disease is widespread, leading to tumor recurrence. Therefore, the use of perioperative NBI en-

doscopy is appropriate for a clearer visualization of superficial laryngeal papillomatosis.

In the future, a new application, using artificial intelligence for real-time detection of laryngeal squamous cell carcinoma, in both white-light videolaryngoscopy and NBI endoscopy, based on a deep learning convolutional neural network, will have a major impact on the refinement of laryngeal cancer diagnosis. This model is already routinely used in colonoscopies and upper gastrointestinal endoscopies (Azam et al., 2022). Wellenstein et al. (2023) recently revealed that the primary version of the Deep Learning algorithm they developed is able to correctly localize and classify benign and malignant vocal cord lesions on still images with a sensitivity between 70–82% and 71–78%, respectively.

In their study, He et al. (2021) reported that the deep convolutional neural network model performed well in the NBI and pathological diagnosis of laryngeal squamous cell carcinoma. More accurate and faster diagnoses could be achieved with the assistance of this algorithm.

Conclusion

NBI endoscopy is a complementary optical method that allows for the improvement of laryngeal lesions diagnosis, the performance of a controlled perioperative biopsy, and the improvement of surgical scope. NBI endoscopy is a suitable method for the diagnosis of early cancerous lesions of the larynx. The use of preoperative/perioperative NBI endoscopy allowed us to achieve a high level of correlation ($p < 0.001$) between the pre-histological working diagnosis and the final histopathological result. The NBI method proves its application in the diagnosis of pre-tumor and tumor lesions of the larynx.

Authors' contribution

All authors contributed to the conception and design of the study. All authors have read and agreed to the published version of the manuscript. All authors gave their consent for publication. Conceptualization, R.H., T.F. and J.A.; validation, T.F., D.Ka., Š.Z., J.H., E.L. and R.H.; investigation, T.F., E.L. and R.H.; resources, R.H., T.F., D.Ka., Š.Z., E.L., D.Ko. and J.A.; data curation, T.F., R.H., D.Ka., J.H. and J.A.; formal analysis, R.H., J.H., D.Ko., D.Ka. and J.A.; writing- original draft preparation,

T.F. and R.H.; writing-review and editing, R.H., T.F., D. Ko., Š.Z. and D.Ka.; visualization, R.H., Š.Z., E.L., D.Ko., J.H. and T.F.; supervision, R.H. and J.A.; project administration, R.H.; funding acquisition, R.H. and J.A.

Ethical aspects and conflict of interest

The authors have no conflict of interest to declare.

Funding

Our prospective study was approved by the Ethics Committee of the Military University Hospital Prague – Reference Number 108/17-29/2022. All patients signed an informed consent form. This research was funded by Project MO 1012 of the Ministry of Defence of the Czech Republic and by the Cooperation Program, research area SURG., Charles University, Czech Republic.

References

- Adachi K, Umezaki T, Kiyohara H, Komune S (2015). New technique for laryngomicrosurgery: narrow band imaging-assisted videolaryngomicrosurgery for laryngeal papillomatosis. *J Laryngol Otol* 129(Suppl. 2): S74–S76. DOI: 10.1017/S0022215114002436.
- Azam MA, Sampieri C, Ioppi A, Africano S, Vallin A, Mocellin D, et al. (2022). Deep Learning Applied to White Light and Narrow Band Imaging Videolaryngoscopy: Toward Real-Time Laryngeal Cancer Detection. *Laryngoscope* 132(9): 1798–1806. DOI: 10.1002/lary.29960.
- Bolontrade MF, Stern MC, Binder RL, Zenklusen JC, Gimenez-Conti IB, Conti CJ (1998). Angiogenesis is an early event in the development of chemically induced skin tumors. *Carcinogenesis* 19(12): 2107–2113. DOI: 10.1093/carcin/19.12.2107.
- Campo F, Ralli M, Di Stadio A, Greco A, Pellini R, de Vincentiis M (2022). Role of Narrow Band Imaging Endoscopy in Preoperative Evaluation of Laryngeal Leukoplakia: A Review of the Literature. *Ear Nose Throat J* 101(9): NP403–NP408. DOI: 10.1177/0145561320973770.
- Dippold S, Becker C, Nusseck M, Richter B, Echternach M (2015). Narrow Band Imaging: A Tool for Endoscopic Examination of Patients With Laryngeal Papillomatosis. *Ann Otol Rhinol Laryngol* 124(11): 886–892. DOI: 10.1177/0003489415590656.
- He Y, Cheng Y, Huang Z, Xu W, Hu R, Cheng L, et al. (2021). A deep convolutional neural network-based method for laryngeal squamous cell carcinoma diagnosis. *Ann Transl Med* 9(24): 1797. DOI: 10.21037/atm-21-6458.
- Holý R, Filipovský T, Veldová Z, Kovář D, Astl J (2018). 10leté zkušenosti s využitím moderních optických metod v diagnostice nádorů hrtanu. [10-years of experience with the use of modern optical methods in the diagnosis of laryngeal tumors]. *Otorinolaryngol Foniatr* 67(2): 84.
- Lu G, Guo W, Zhang Q, Song X (2021). Endoscopic diagnosis value of narrow band imaging Ni classification in vocal fold leukoplakia and early glottic cancer. *Am J Otolaryngol* 42(3): 102904. DOI: 10.1016/j.amjoto.2021.102904.
- Lukes P, Zabrodsky M, Lukesova E, Chovanec M, Astl J, Betka JA, Plzak J (2014). The role of NBI HDTV magnifying endoscopy in the prehistologic diagnosis of laryngeal papillomatosis and spinocellular cancer. *Biomed Res Int* 2014: 285486. DOI: 10.1155/2014/285486.
- Missale F, Taboni S, Carobbio ALC, Mazzola F, Berretti G, Iandelli A, et al. (2021). Validation of the European Laryngological Society classification of glottic vascular changes as seen by narrow band imaging in the optical biopsy setting. *Eur Arch Otorhinolaryngol* 278(7): 2397–2409. DOI: 10.1007/s00405-021-06723-7.
- Mlčochová G, Jurovcik M, Matas M, Janota J (2020). Kongenitální laryngeální cysta. *Neonatologické listy* 26(1): 12–14.
- Muscas G, Battista F, Boschi A, Morone F, Della Puppa A (2021). A Single-Center Experience with the Olympus ORBEYE 4K-3D Exoscope for Microsurgery of Complex Cranial Cases: Technical Nuances and Learning Curve. *J Neurol Surg A Cent Eur Neurosurg* 82(5): 484–489. DOI: 10.1055/s-0040-1719106.
- Ni XG, He S, Xu ZG, Gao L, Lu N, Yuan Z, et al. (2011). Endoscopic diagnosis of laryngeal cancer and precancerous lesions by narrow band imaging. *J Laryngol Otol* 125(3): 288–296. DOI: 10.1017/S0022215110002033.
- Ni XG, Zhu JQ, Zhang QQ, Zhang BG, Wang GQ (2019). Diagnosis of vocal cord leukoplakia: The role of a novel narrow band imaging endoscopic classification. *Laryngoscope* 129(2): 429–434. DOI: 10.1002/lary.27346.
- Piazza C, Cocco D, De Benedetto L, Bon FD, Nicolai P, Peretti G (2010). Role of narrow-band imaging and high-definition television in the surveillance of head and neck squamous cell cancer after chemo- and/or radiotherapy. *Eur Arch Otorhinolaryngol* 267(9): 1423–1428. DOI: 10.1007/s00405-010-1236-9.
- Piazza C, Cocco D, Del Bon F, Mangili S, Nicolai P, Peretti G (2011). Narrow band imaging and high-definition television in the endoscopic evaluation of upper aero-digestive tract cancer. *Acta Otorhinolaryngol Ital* 31(2): 70–75.
- Saraniti C, Gallina S, Verro B (2022). NBI and Laryngeal Papillomatosis: A Diagnostic Challenge: A Systematic Review. *Int J Environ Res Public Health* 19(14): 8716. DOI: 10.3390/ijerph19148716.
- Šatanková J, Staníková L, Švejdová A, Černý M, Laco J, Chrobok V (2021). Diagnostic Value of Narrow Band Imaging in Visualization of Pathological Lesions in Larynx and Hypopharynx. *Acta Medica (Hradec Kralove)* 64(1): 22–28. DOI: 10.14712/18059694.2021.4.
- Slouka D (Ed.), Rusnak S, Fikrlé T, Poleník P (2015). *Lasery při výkonech v ambulantní a klinické praxi* (1st ed.). Plzeň: Euroverlag, s.r.o.
- Staníková L, Kučová H, Walderová R, Zeleník K, Šatanková J, Komínek P (2015). Využití Narrow Band Imaging v diagnostice časných karcinomů hrtanu [Value of narrow band imaging endoscopy in detection of early laryngeal squamous cell carcinoma]. *Klin Onkol* 28(2): 116–120. DOI: 10.14735/amko2015116.
- Wellenstein DJ, Woodburn J, Marres HAM, van den Broek GB (2023). Detection of laryngeal carcinoma during endoscopy using artificial intelligence. *Head Neck* 45(9): 2217–2226. DOI: 10.1002/hed.27441.